

Circulation

JOURNAL OF THE AMERICAN HEART ASSOCIATION



Catheter Ablation of Paroxysmal Atrial Fibrillation Using a 3D Mapping System

Carlo Pappone, Giuseppe Oreto, Filippo Lamberti, Gabriele Vicedomini, Maria Luisa Loricchio, Shlomo Shpun, Mariano Rillo, Maria Pia Calabrò, Andrea Conversano, Shlomo A. Ben-Haim, Riccardo Cappato and Sergio Chierchia

Circulation 1999;100;1203-1208

Circulation is published by the American Heart Association, 7272 Greenville Avenue, Dallas, TX 72514

Copyright © 1999 American Heart Association. All rights reserved. Print ISSN: 0009-7322. Online ISSN: 1524-4539

The online version of this article, along with updated information and services, is located on the World Wide Web at:

<http://circ.ahajournals.org/cgi/content/full/100/11/1203>

Subscriptions: Information about subscribing to *Circulation* is online at
<http://circ.ahajournals.org/subscriptions/>

Permissions: Permissions & Rights Desk, Lippincott Williams & Wilkins, a division of Wolters Kluwer Health, 351 West Camden Street, Baltimore, MD 21202-2436. Phone: 410-528-4050. Fax: 410-528-8550. E-mail:
journalpermissions@lww.com

Reprints: Information about reprints can be found online at
<http://www.lww.com/reprints>

Catheter Ablation of Paroxysmal Atrial Fibrillation Using a 3D Mapping System

Carlo Pappone, MD; Giuseppe Oreto, MD; Filippo Lamberti, MD; Gabriele Vicedomini, MD; Maria Luisa Loricchio, MD; Shlomo Shpun, DSc; Mariano Rillo, MD; Maria Pia Calabrò, MD; Andrea Conversano, MD; Shlomo A. Ben-Haim, MD, DSc; Riccardo Cappato, MD; Sergio Chierchia, MD

Background—We treated paroxysmal recurrent atrial fibrillation (AF) with radiofrequency (RF) catheter ablation by creating long linear lesions in the atria. To achieve line continuity, a 3D electroanatomic nonfluoroscopic mapping system was used.

Methods and Results—In 27 patients with recurrent AF, a catheter incorporating a passive magnetic field sensor was navigated in both atria to construct a 3D activation map. RF energy was delivered to create continuous linear lesions: 3 lines (intercaval, isthmus, and anteroseptal) in the right atrium and a long line encircling the pulmonary veins in the left atrium. After RF application, the atria were remapped to validate completeness of the block lines, demonstrated by late activation of the areas circumscribed by the lines. The mean procedure duration was 312 ± 103 minutes (range, 187 to 495), with mean fluoroscopy time of 107 ± 44 minutes (range, 32 to 185 minutes). No acute complications occurred, but 1 patient experienced early prolonged sinus pauses and received a pacemaker. During the first day, 17 patients (63%) had AF episodes, but at discharge, 25 patients were in sinus rhythm. After a follow-up of 6.0 to 15.3 months (average, 10.5 ± 3.0 months), 16 patients are asymptomatic, 3 have an almost complete disappearance of symptoms, 1 patient is improved, and 7 patients have their AF attacks unchanged.

Conclusions—Paroxysmal recurrent drug-refractory AF can be treated by RF catheter ablation. Creation of long continuous linear lesions necessary to compartmentalize the atria is facilitated by a nonfluoroscopic electroanatomic mapping system. (*Circulation*. 1999;100:1203-1208.)

Key Words: catheter ablation ■ fibrillation ■ mapping

Atrial fibrillation (AF) is the most common tachyarrhythmia,¹ its prevalence being $\approx 5\%$ in people >65 years old.² Current therapeutic strategies include antiarrhythmic drugs and electrical cardioversion. More recently, alternative treatments, such as catheter ablation or modulation of the atrioventricular (AV) node,³ implantation of an atrial defibrillator,⁴ and surgical procedures^{5,6} have been proposed.

Very recently, the possibility of treating AF by means of radiofrequency (RF) catheter ablation has been reported.^{7,8} The nature of AF makes a transcatheter approach difficult, because lesions generated with this technique are small and apparently inadequate to modify the substrate of this arrhythmia.

The present study was designed to test the hypothesis that a nonfluoroscopic electroanatomic mapping system might assist in the creation and verification of linear transcatheter RF lesions in patients with paroxysmal AF.

Methods

Patients

We studied 27 patients with symptomatic, recurrent, drug-refractory paroxysmal AF lasting for ≥ 1 year. There were 20 men and 7

women, with a mean age of 45.8 ± 11.6 years (range, 27 to 67 years). Only 2 patients had structural heart disease, 1 hypertrophic cardiomyopathy, and 1 mitral valve prolapse. Correctable causes of AF, such as thyroid disease, had been excluded, and all patients were nonresponders to antiarrhythmic drugs (average of 3.6 ± 1.5 drugs per patient). Amiodarone had been used in 9 patients but at the time of the study had been withdrawn in each patient for at least 3 months. Before inclusion in the protocol, every patient underwent extensive observation throughout 1 month. Two 24-hour Holter recordings were performed to obtain documentation of episodes of AF and to demonstrate the correspondence of the arrhythmia with symptoms. Patients were also provided with an event report to record every episode of AF with particular regard to its duration. Inclusion in the study required, over 3 weeks, a minimum of 3 episodes per week, with duration >1 hour (Table).

Electrophysiological Study

The study protocol was approved by the ethics committee of the San Raffaele Hospital; patients were informed about the experimental nature of the procedure and its related risks and gave written informed consent. Antiarrhythmic drugs were discontinued for ≥ 5 half-lives. The electrophysiological study was performed in accordance with the standard technique. Quadripolar 6F catheters were placed in the coronary sinus (CS) and in the right ventricular apex.

Received July 27, 1998; revision received June 14, 1999; accepted June 17, 1999.

From the Cardiology Department, Hospital S. Raffaele, Milan, Italy (C.P., F.L., G.V., M.L.L., M.R., A.C., S.C.); the Cardiology Department, University of Messina, Messina, Italy (G.O., M.P.C.); the Cardiovascular System Laboratory, Rappaport Faculty of Medicine, Technion-Israel Institute of Technology, Haifa, Israel (S.S., S.A.B.-H.); and the Allgemeines Krankenhaus St Georg, II Medizinische Abteilung, Hamburg, Germany (R.C.).

Correspondence to Carlo Pappone, MD, Divisione di Cardiologia, Ospedale S Raffaele, Via Olgettina, 60, 20132 Milano, Italy.

© 1999 American Heart Association, Inc.

Circulation is available at <http://www.circulationaha.org>

Data Obtained From Patients' Diaries, Clinical Visits, and Holter Recordings

Patient	Run-In Phase					Postablation Period					Drug
	Week 1 Episodes of AF	Week 2 Episodes of AF	Week 3 Episodes of AF	Episode Duration, h	Type of Ablative Approach	Rhythm on Day 1	Rhythm on Discharge	Week 1 Episodes of AF	Month 1 Episodes of AF	Months 3–6 Episodes of AF	
1	3	7	5	1–4	LA+RA	SR	SR	0	0	0	...
2	4	3	4	2–12	LA+RA	SR	SR	0	0	0	...
3*	7	5	4	1–8	LA+RA	AF	AF	>10	>10	>10	...
4	4	2	3	0.5–3	LA+RA	SR	SR	0	0	0	...
5	3	5	3	1–6	LA+RA	SR	SR	0	0	0	
6	5	1	3	2–8	LA+RA	AF	SR	0	2	2	S
7*	3	3	3	1–18	LA+RA	SR	SR	1	>10	>10	F
8	11	4	6	0.5–2	LA+RA	AF	SR	0	0	0	
9*	7	2	8	2–4	LA+RA	AF	SR	1	0	0	Q
10	3	6	4	1–24	LA+RA	AF	SR	0†	0	0	S
11	5	3	NA	3–8	LA+RA	AF	SR	SR	1	2	F
12	3	3	NA	2–3	LA+RA	SR	SR	0	0	0	...
13	6	2	3	0.5–8	LA+RA	AF	SR	0	0	0	...
14	8	11	9	0.5–1	LA+RA	SR	SR	0	0	0	...
15*	4	3	3	2–4	LA	AF	AF	2	>10	>10	P
16	2	5	3	0.5–1	LA	AF	SR	0	0	0	...
17	5	3	2	2–3	LA	SR	SR	0	0	0	...
18*	3	4	5	1–2	LA	AF	SR	2	>10	>10	S
19	6	3	3	0.5–2	LA	AF	SR	0	0	0	...
20	3	3	4	1–12	RA	AF	SR	1	0	0	P
21	5	5	NA	2–4	RA	AF	SR	0	0	0	...
22	3	5	3	1–4	RA	SR	SR	3	>10	>10	S
23	6	4	4	1–12	RA	AF	SR	0	2	>10	P
24	7	4	NA	1–2	RA	AF	SR	0	1	3	S
25	4	2	4	1–2	RA	AF	SR	0	1	>10	S
26	6	4	NA	1–2	RA	AF	SR	0	0	0	P
27*	4	3	NA	4–8	RA	AF	SR	1	2	>10	P

NA indicates not available; SR, sinus rhythm; S, sotalol; F, flecainide; Q, quinidine; P, propafenon. Number of AF episodes during the run-in period (3 weeks) and range of episode duration (hours). Rhythm observed during postablation follow-up at day 1 and at discharge. Number of AF episodes at follow-up, during the first postdischarge week, at 1 month, and at 3 to 6 months. Drug treatment.

*Incomplete lines of block.

†Atrial tachycardia.

A pigtail catheter was placed in the ascending aorta to obtain continuous arterial pressure monitoring. A reference catheter (Ref-Star, Cordis-Webster) was placed on the back of the patient, and a deflectable-tip catheter (Navi-Star, Cordis-Webster) was used for mapping and ablation. Left atrial (LA) catheterization was obtained by a transseptal route with a standard Brockenbrough needle and a long sheath.

Mapping System

The nonfluoroscopic navigation and mapping system has already been described.^{9–11} The system is composed of a miniature passive magnetic field sensor incorporated into a standard electrophysiological catheter, an external ultralow magnetic field emitter (location pad), and a processing unit (Carto, Biosense). Ultralow magnetic fields are emitted from the location pad; the spatial and temporal characteristics of the sensed magnetic fields contain the information needed to solve a set of overdetermined algebraic equations yielding the location (*x*, *y*, and *z*) and orientation (roll, yaw, and pitch) of the catheter tip. The resolution of the location capabilities of the system

was quantified previously and shown to be <1 mm for both in vitro and in vivo studies.¹² This information allows tracking of the tip of the mapping catheter while it is deployed within the heart.

Mapping Process

The mapping and ablation procedures were performed during continuous CS pacing at a rate of 100 bpm. The mapping catheter was introduced into the atria under fluoroscopic guidance, and its location was recorded relative to the location of the fixed reference catheter. By moving the catheter inside the heart, the mapping system continuously analyzed its location and orientation and presented it to the user on the monitor of a graphic workstation, thereby allowing navigation without the use of fluoroscopy.

The mapping procedure was based on dragging the catheter over the endocardium and sequentially acquiring the location of its tip together with its electrogram while in contact with the endocardium. 3D chamber geometry was reconstructed in real time by use of the set of location points sampled from the endocardium. The local activation time (LAT) at each site was determined as the time

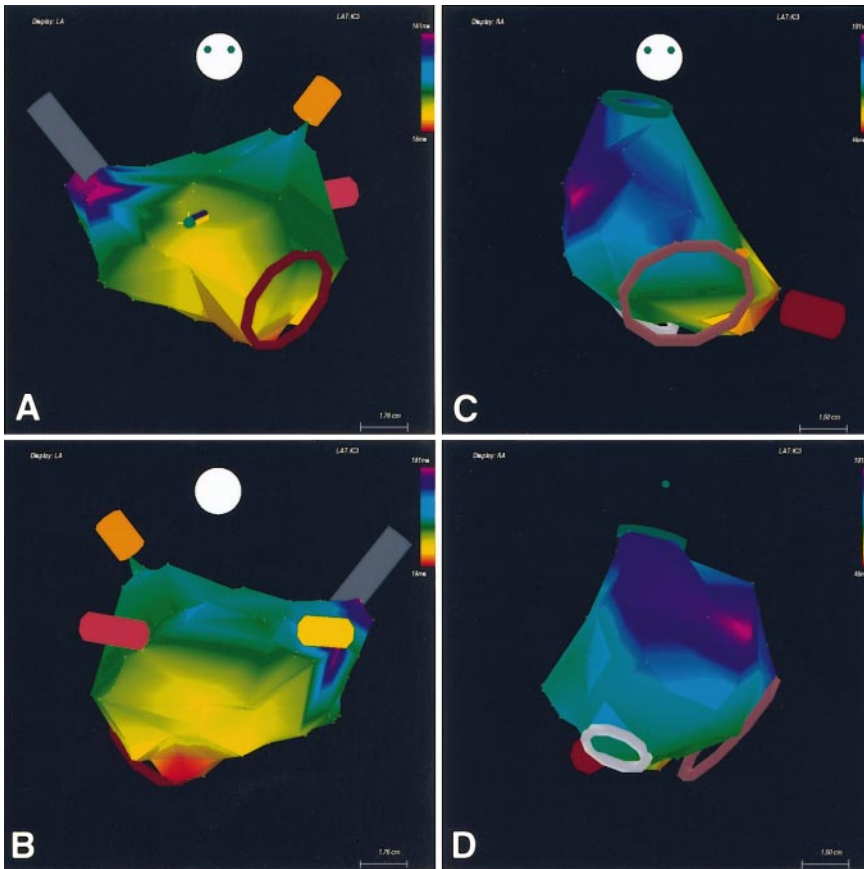


Figure 1. LA and RA electroanatomic map during CS pacing. LA anteroposterior view (A) and posteroanterior view (B) showing pulmonary veins protruding from posterior LA wall. Note catheter icon during mapping procedure (A); catheter tip (dark green ellipsoid) is pointing down. RA anteroposterior view (C) and right lateral view (D) showing tricuspid annulus (brown ring), superior vena cava (green ring), inferior vena cava (gray ring), and CS (red tube). Color-coding of electroanatomic maps represents activation times (red represents earliest activation time and purple represents latest activation time).

interval between the pacing artifact and the steepest negative intrinsic deflection in the unipolar electrogram recorded from the catheter tip. The stability of the catheter-to-endocardium contact was evaluated on the basis of (1) end-diastolic stability (the distance in millimeters between 2 successive endocardial locations) and (2) LAT stability (the interval in milliseconds between 2 successive LATs). A point was added to the map only if the end-diastolic stability was <2 mm and the LAT stability was <2 ms.^{10,12} For each atrial chamber, a number of points ranging from 50 to 110 was taken (average, 81 ± 14).

On the basis of the various LATs, a map was constructed showing the activation sequence resulting from the time of activation of different zones in a cardiac chamber. The activation map was color-coded (red indicating the earliest and purple the latest activation) and superimposed on the 3D chamber geometry (Figure 1).

RF Application

RF energy was delivered via the distal electrode of the NAVI-STAR catheter. RF power was titrated to achieve a temperature of 65°C in the right atrium (RA) or 55°C in the LA. A maximum power of 60 W was used for 60 to 120 seconds, with the target of reducing the amplitude of the local electrogram by $\geq 75\%$ of the initial value. Any linear lesion was composed of a series of focal lesions, whose location was tagged on the map (Figures 2 through 4).

In the RA, 3 linear lesions were designed: (1) posterior intercaval; (2) medial isthmus, between the IVC and the tricuspid annulus; and (3) septal, between the superior aspect of the intercaval line and the posteroseptal tricuspid annulus. The anteroseptal line was intentionally left incomplete in the upper part to avoid isolation of the sinus node. In the LA, 1 long lesion was generated, encircling the

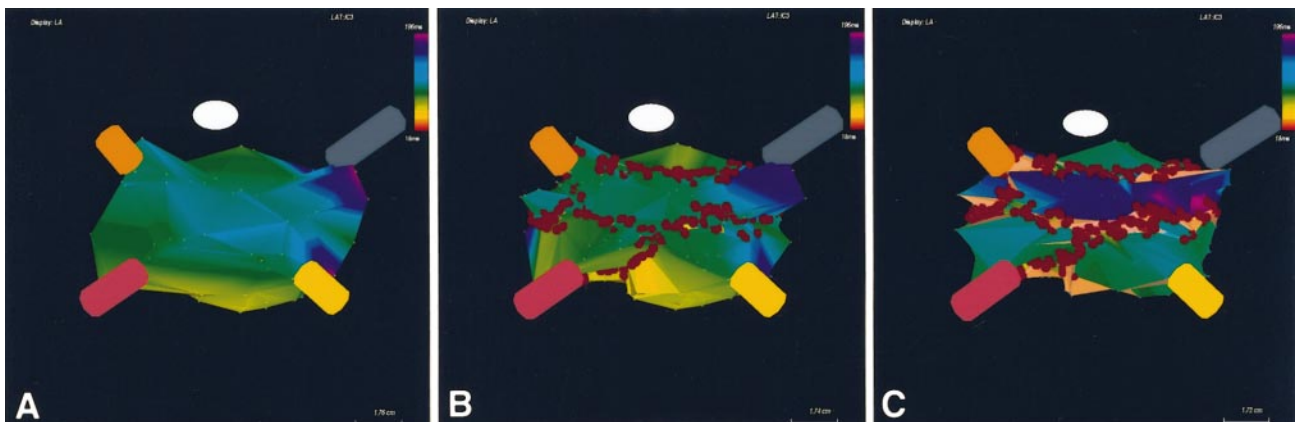


Figure 2. LA maps (coronal view). A and B, Preablation and postablation maps, respectively. Red spheres indicate sites at which RF energy was deployed. Note ablation line, encircling superior pulmonary veins (B). C, Postablation remapping of LA.




Figure 3. Mapping and remapping of RA after delivery of long continuous ablation lines, during pacing from distal CS. Brown ring depicts tricuspid annulus, gray ring inferior vena cava, and red tube CS. A, Basic map; B, ablation line design (particularly isthmal line); and C, postablation remapping. Note late activation, revealed by dark blue color, in area isolated by 3 ablation lines.

pulmonary veins and connected to the mitral annulus on 2 sides (Figure 2B).

After the planned lines of block had been created, the atria were remapped, and the preablation and postablation activation maps were compared. The result was considered satisfactory whenever there was no evident impulse propagation across the line of block but the depolarization wave front reached the region beyond the block over a different route. An incomplete block was revealed by impulse propagation through the line, shown by an identical color in points lying at the same level on the 2 sides of the line; in such a case, further RF pulses were given to complete the line of block. We assumed arbitrarily that a line of block was “complete” when there was a difference in activation time by ≥ 60 ms between 2 points at the same level at the 2 sides of a line separated from each other by a distance of < 1 cm.

Results

The biatrial approach was used in 14 patients, isolated LA ablation in 5 patients, and isolated RA ablation in 8. The mean procedure duration (\pm SD) was 312 ± 103 minutes (range, 187 to 495 minutes), with mean fluoroscopy time of 107 ± 44 minutes (range, 32 to 185 minutes). In the last 13 cases, fluoroscopy time was significantly reduced compared with the earlier ones (70 ± 24 versus 144 ± 22 minutes, $P < 0.01$; Student’s *t* test for unpaired data). Fluoroscopy was used only to insert the catheters, to identify the anatomic landmarks, and to perform the

transseptal approach, whereas the collection of location points was achieved mainly without fluoroscopy.

The average number of RF pulses was 98 ± 21 for LA ablation and 61 ± 15 for RA ablation. In 21 patients, postablation verification demonstrated the completeness of the lines of block, whereas in 6 patients, no such demonstration was obtained despite several additional RF applications in sites corresponding to possible “holes.”

The post-RF changes in activation maps are evident from Figures 2, 3, and 4. Figure 2A shows progressive color transition throughout the atrial walls: points close to each other reflect either the same color or a small color difference, corresponding to activation 10 to 20 ms apart, whereas in Figure 2C, the lines of block, indicated by red tags, separate zones with totally different colors, ie, activation > 60 ms apart. This means that the activation wave front does not cross the line. The postablation remapping (Figure 2C) demonstrates that the area encircled by the line of block has late activation colors (dark blue to purple), the expression of late arrival of the activation wave front to this area. The same phenomenon is evident in Figures 3 and 4. Figure 3 shows an inferomedial view of the RA; 3A reflects the preablation map, 3B the designed line of block, and 3C the postablation map.

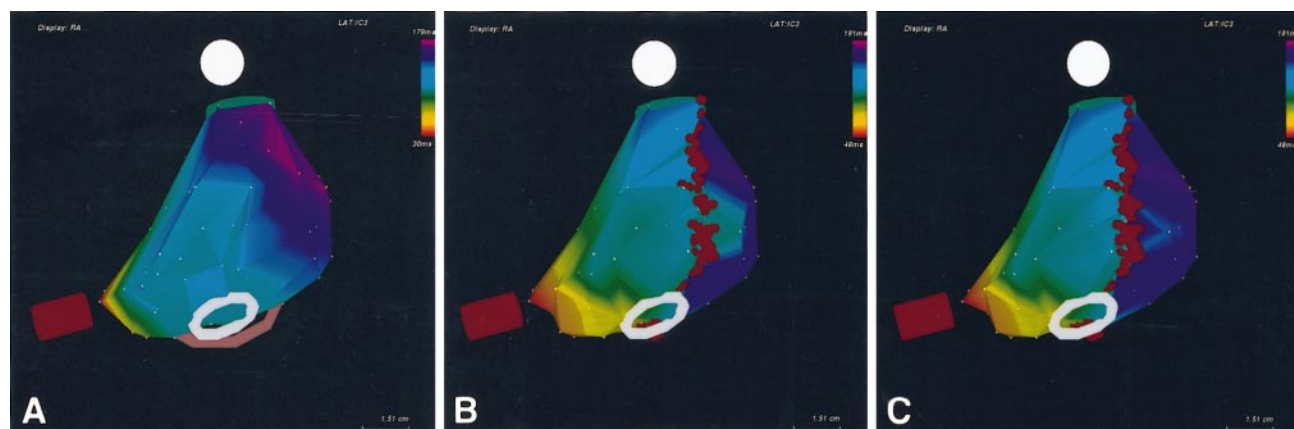


Figure 4. Mapping and remapping of RA (right posterolateral view). A, Basic map; intercaval ablation line (red spheres) is evident in B and C. B, Incomplete line of block: a breakthrough along line is revealed by identical color (green) on 2 sides of line. Remapping after further RF application in critical area demonstrates a complete line of block (C).

Again, the area circumscribed by the lines of block has late activation colors, whereas it had mostly early activation colors in the preablation map. This demonstrates that the lines of block prevent a normal intra-atrial impulse conduction, resulting in late activation of the RA free wall.

Figure 4 shows the results of linear lesions deployed in an RA (the posterior intercaval line). Panel A depicts the preablation map and B and C postablation maps. In the first post-RF map (B), the line of block is incomplete, as suggested by the presence, in the lower half of the line, of areas reflecting the same color (green) on the 2 sides of the line. The map shown in C, obtained after further RF application to the critical site, suggests that the line of lesion is complete (no indistinguishable colors at matched points on the 2 sides of the line).

Effects of the Ablation Procedure on AF

Catheter ablation resulted in relevant reduction of AF attacks in most patients. After a follow-up of 6.0 to 15.3 months (average, 10.5 ± 3.0 months), 16 of 27 treated patients are asymptomatic (4 on drugs), 3 have almost complete disappearance of symptoms (all 3 on drugs), 1 patient is improved in terms of number and duration of episodes, and the remaining 7 show no change in their AF episodes (Table).

No complications occurred during the procedures, but 1 patient had complications in the early follow-up. Twenty-four hours after the procedure, transthoracic and transesophageal echocardiograms were unchanged in 24 patients, whereas in 3, a slight pericardial effusion was demonstrated. This was not associated with symptoms or signs of pericarditis and disappeared at the 1-week control without any treatment. Evaluation of mechanical atrial function by means of Doppler mitral and tricuspid flow analysis did not demonstrate any change after the ablation procedure: the E/A transmitral flow velocity ratio was 1.37 ± 0.5 versus 1.37 ± 0.47 before and after catheter ablation, respectively.

At the end of the ablation session, all patients were in sinus rhythm, as at the beginning of the procedure, but 17 patients (63%) suffered from AF during the 24 hours after the procedure, with episodes ranging from a few minutes to several hours. A 67-year-old woman experienced episodes of AF followed by sinus pauses as long as 6 seconds; she underwent implantation of a DDD pacemaker. After this patient, we started leaving the anteroseptal line in the RA incomplete, in an attempt to prevent sinus node dysfunction. Analysis of Holter recordings did not reveal any sign of sinus node disease in the last 24 patients.

Predischarge Holter recording showed atrial extrasystoles in all patients, paroxysmal atrial flutter with a duration of 30 minutes in 1 patient, and brief AF episodes in 7 patients.

At 1 week from discharge, 19 patients were free of AF (disappearance of symptoms, no Holter evidence of the arrhythmia). Seven of them had frequent atrial extrasystoles at Holter monitoring, and 1 patient experienced an ECG-documented episode of atrial tachycardia at a rate of 140 bpm. The remaining 8 patients had recurrent episodes of AF. One month after the procedure, 16 patients (4 on drugs) were asymptomatic and had no AF. Seven patients had isolated episodes of AF (no more than 2 episodes during 1 month), and the remaining 4 had no change in symptoms.

Three months after ablation, 16 patients were free of recurrence, whereas 3 patients had isolated episodes of AF. One patient had recurrence of AF but with fewer and shorter episodes than before. In 7 patients (26%), including 5 of 6 in whom no complete ablation lines had been obtained, AF episodes were unchanged. At 6 months, no change occurred in comparison with the 3-month follow-up.

The procedure was successful in eliminating or significantly reducing AF in 12 of 14 patients (85%) with the biatrial approach, in 3 of 5 patients (60%) who underwent isolated LA ablation, and in 4 of 8 patients (50%) in whom only RA ablation was performed.

Discussion

RF catheter ablation appears promising in the treatment of paroxysmal AF. Our data reveal that 19 patients (70%) were treated successfully (16 totally asymptomatic, 3 with a dramatic reduction of symptoms) and 1 patient improved, whereas in 7 patients (21%), the arrhythmia was unchanged. Although the follow-up is limited and some recurrences could have been undetected by Holter recordings and/or unrecognized by the patients, all of them were so highly symptomatic that it is not difficult to assume that in the successful group the arrhythmia was either eliminated or significantly reduced.

Rationale for Ablation Techniques in AF

Ablation treatment for AF is based on the hypothesis that without a relatively large atrial mass in which to operate, multiple reentrant wavelets sufficient in number to perpetuate AF cannot coexist. If so, AF may be cured by dividing the atria into several areas electrically isolated from each other. This procedure was originally applied by Cox et al,⁵ who introduced the maze operation. The favorable results achieved by surgeons led to preliminary laboratory investigation of RF catheter ablation of AF in animals and subsequent application in humans.^{7,8,13-15}

Target of Ablation in AF

The present study, as well as previous reports, suggests that catheter ablation is suitable for the treatment of AF. The target of ablation and the number of linear lesions to be created, however, are still debatable. A biatrial approach appears preferable to either isolated LA or RA ablation, because the success rate was 85% in patients with biatrial ablation, whereas it was only 50% to 60% of patients in whom 1 single atrium had been approached. The number of patients in each group, however, is too small to permit statistical analysis. In a study by Haïssaguerre,⁷ biatrial ablation was also associated with a higher success rate than RA ablation alone.

A relevant technical problem in AF ablation concerns the "completeness" of ablation lines, because incomplete electrical separation between contiguous areas is likely to permit impulse conduction sufficient for propagation of fibrillatory wave fronts. With current ablation technology, creation of complete ablation lines is difficult: it is hard to assess the continuity of a long linear lesion just by looking at the movements of the catheter tip on the fluoroscopic screen. In contrast, the technique based on 3D electroanatomic mapping permits us to evaluate the completeness of the linear lesion, because each lesional point is tagged on

the map, so that interruptions in line continuity may be easily identified, and further RF applications in critical regions may succeed in completing the lines (Figure 4).

It was not possible in every case, however, to achieve complete lines of block resulting in significant change of the activation map: in 6 patients, no complete lines were obtained despite additional RF applications. In these patients, the possible holes were filled with further lesions, and an uninterrupted series of tags was achieved, but no satisfactory change in activation resulted. Identification of line continuity relies on a critical change in activation rather than being expressed as an uninterrupted series of tags.

“Completeness” of the line of block, in our definition, means a delay of conduction ≥ 60 ms between points close to each other, whereas “incompleteness” of block indicates a lesser degree of conduction delay or normal conduction. Completeness of the line judged by change in activation map does not imply total absence of conduction across the line of block but rather merely indicates that the route of propagation of the impulse front is different with respect to the previous condition. Theoretically, therefore, a circulating wave front could still traverse the line of block, despite a significant postablation change of the activation map, which might account for some recurrences of the arrhythmia after achievement of complete lines of block.

Postablation AF

The incidence of AF on the day after the ablation procedure was very high in this study. It is difficult to assess the mechanism leading to acute postablation AF, but we can assume that the phenomenon is similar to that described after the maze operation. In 47% of patients undergoing the maze surgical procedure, AF developed in the early postoperative period, even though in the follow-up, 98% of patients were free of recurrence, and 89% of them did not take any antiarrhythmic medication. Cox et al⁶ explained such a finding by assuming a postoperative shortening of the atrial refractory period, allowing initiation and maintenance of AF despite the absence of atrial areas large enough to permit the arrhythmia under normal conditions. This is because shortening of the refractory period significantly decreases the critical mass necessary for reentry. It is possible that in our patients, the edema associated with the large number of endocardial lesions shortened the atrial refractory period in such a way that AF occurred in the early postprocedure time. This is not the only possible explanation for postoperative AF; enhancement of ectopic automaticity could also play a role.

Limitations of the Study

We treated only patients with paroxysmal AF and without significant anatomic atrial involvement. The present results thus cannot be extended to patients with chronic AF and diseased atria. Moreover, the technique is based on mapping and RF delivery during constant atrial pacing from the CS, which facilitates comparison of preablation and postablation maps. Treatment of patients with chronic AF requires a different approach, because atrial pacing is impossible, so that preablation and postablation maps cannot be compared in the manner described here.

The procedure is long because mapping and remapping of the atria require acquisition of a large number of points. Although in

our limited series we had no complications related to transseptal catheterization and long-lasting catheter manipulation in the left heart, such an approach should be considered to carry some risk of thromboembolism. Finally, the long-term outcome of the procedure is unknown, and theoretically AF could recur if recovery of conduction in some areas again allows the coexistence of multiple reentrant wavelets.

Conclusions

Paroxysmal recurrent drug-refractory AF can be treated by RF catheter. Creation of the long continuous linear lesions necessary to compartmentalize the atria is facilitated by the use of a nonfluoroscopic electroanatomic mapping system that permits accurate selection of the target sites for RF application as well as evaluation of the completeness of the lesion. The procedure described here is time-consuming and carries some risks. Thus, such an approach should be considered only for patients disabled by their arrhythmia. Further investigation is needed to define the possibility of applying the same procedure to patients with chronic AF.

References

1. Kerr CR, Chung DC. Atrial fibrillation: fact, controversy and future. *Clin Prog Electrophysiol Pacing*. 1985;3:319–337.
2. Furberg CD, Psaty BM, Manolio TA, Gardin JM, Smith VE, Rautaharju PM, CHS Collaborative Research Group. Prevalence of atrial fibrillation in elderly subjects (the Cardiovascular Health Study). *Am J Cardiol*. 1994;74:236–241.
3. Scheinman MM, Morady F, Hess DS, Gonzales R. Catheter-induced ablation of the atrioventricular junction to control refractory supraventricular arrhythmias. *JAMA*. 1982;248:851–855.
4. Lau CP, Tse HF, Lok NS, Lee KLF, Ho DSW, Sopher M, Murgatroyd FD, Camm AJ. Initial clinical experience with an implantable human atrial defibrillator. *Pacing Clin Electrophysiol*. 1997;20:220–225.
5. Cox JL, Schuessler RB, D’Agostino HJ Jr, Stone CM, Chang BC, Cain ME, Corr PB, Boineau JP. The surgical treatment of atrial fibrillation, III: development of a definitive surgical procedure. *J Thorac Cardiovasc Surg*. 1991;101:569–583.
6. Cox JL, Boineau JP, Schuessler RB, Kater KM, Lappas DG. Five year experience with the Maze procedure for atrial fibrillation. *Ann Thorac Surg*. 1993;56:814–824.
7. Haïssaguerre M, Jaïs P, Shah DC, Gencel L, Pradeau V, Garrigues S, Chouairi S, Hocini M, Le Metayer P, Roudaut R, Clementy J. Right and left atrial radiofrequency catheter therapy of paroxysmal atrial fibrillation. *J Cardiovasc Electrophysiol*. 1996;7:1132–1144.
8. Gaita F, Riccardi R, Calò L, Scaglione M, Garberoglio L, Antolini R, Kirchner M, Lamberti F, Richiardi E. Atrial mapping and radiofrequency catheter ablation in patients with idiopathic atrial fibrillation: electrophysiologic findings and ablation results. *Circulation*. 1998;97:2136–2145.
9. Ben-Haim SA, Osadky D, Schuster I, Gepstein L, Hayam G, Josephson ME. Nonfluoroscopic, in vivo navigation and mapping technology. *Nat Med*. 1996;2:1393–1395.
10. Shpun S, Gepstein L, Hayam G, Ben-Haim SA. Guidance of radiofrequency endocardial ablation with real-time three-dimensional magnetic navigation system. *Circulation*. 1997;96:2016–2021.
11. Smeets JLRM, Ben-Haim S, Rodriguez L-M, Timmermans C, Wellens HJJ. New method for nonfluoroscopic endocardial mapping in humans: accuracy assessment and first clinical results. *Circulation*. 1998;97:2426–2432.
12. Hayam G, Gepstein L, Ben-Haim SA. Accuracy of the in vivo determination of location using a nonfluoroscopic electroanatomic mapping system. *Circulation*. 1997;95:1611–1622.
13. Elvan A, Pride HP, Eble JN, Zipes DP. Radiofrequency catheter ablation of the atria reduces inducibility and duration of atrial fibrillation in dogs. *Circulation*. 1995;91:2235–2244.
14. Tondo C, Scherlag BJ, Otomo K, Antz M, Patterson E, Arruda M, Jackman WJ, Lazzara R. Critical site for ablation of pacing-induced atrial fibrillation in the normal dog heart. *J Cardiovasc Electrophysiol*. 1997;8:1255–1265.
15. Sih HJ, Barbari EJ, Zipes DG. Epicardial maps of atrial fibrillation after linear ablation lesions. *J Cardiovasc Electrophysiol*. 1997;8:1046–1054.